

Kunkmann-Wolffian bodies

Category(ies): Glaucoma, Iris

Contributor: [Jesse Vislisel, MD](#)

Photographer: Antoinette Venckus, CRA

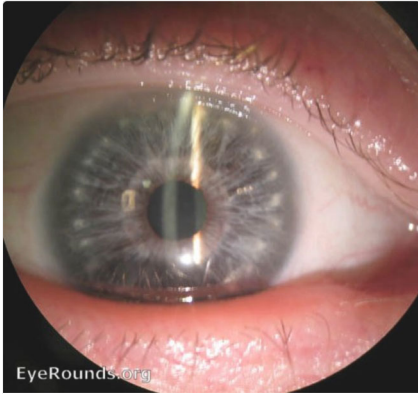
Kunkmann-Wolffian bodies are hypopigmented areas of peripheral iris stromal hyperplasia in patients without Down syndrome. They are clinically indistinguishable from [Brushfield spots](#) which are seen in individuals with Down syndrome.

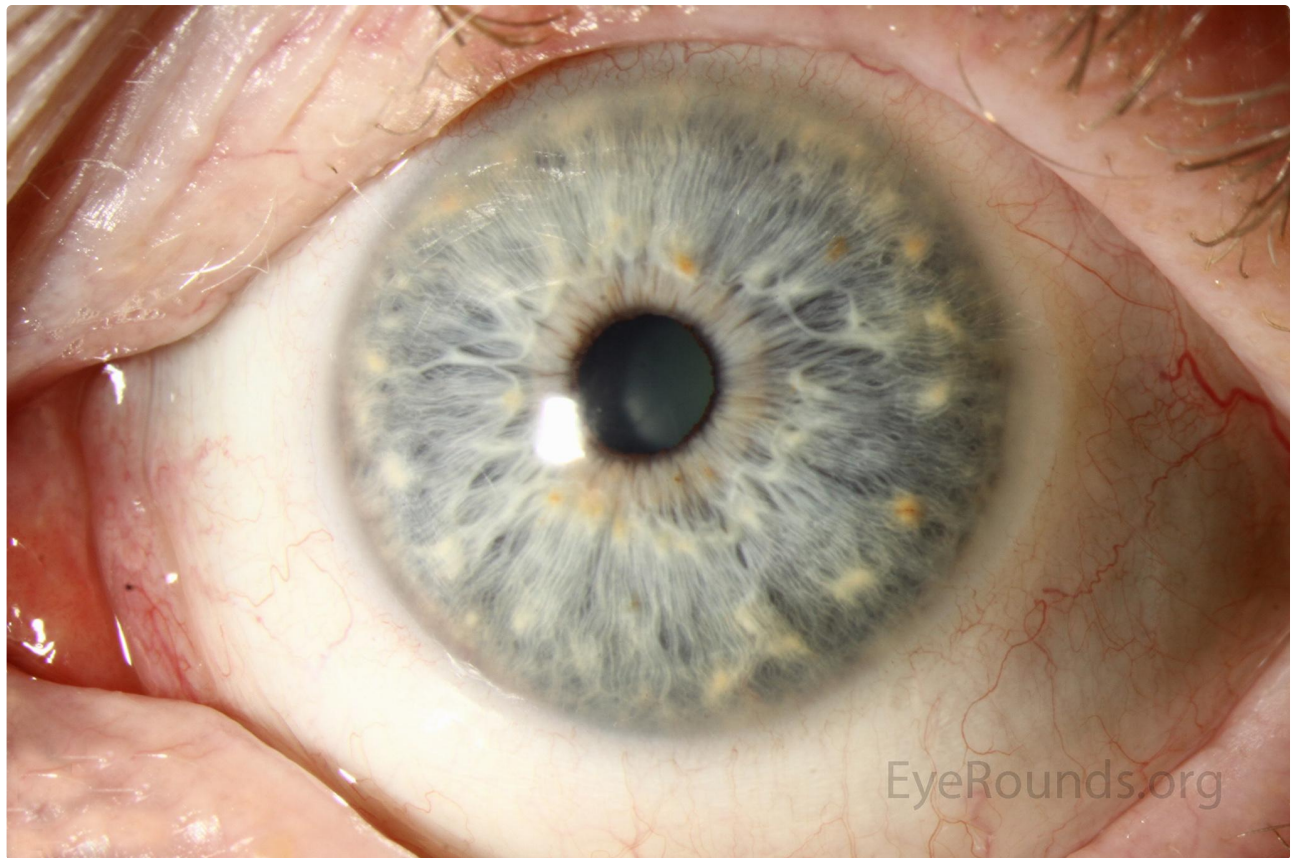

Image Permissions:



Ophthalmic Atlas Images by [EyeRounds.org, The University of Iowa](#) are licensed under a [Creative Commons Attribution-NonCommercial-NoDerivs 3.0 Unported License](#).



[Related Atlas Entry: Down's Syndrome with Brushfield's spots on the iris](#)

Address

University of Iowa
Roy J. and Lucille A. Carver College
of Medicine
Department of Ophthalmology and
Visual Sciences
200 Hawkins Drive
Iowa City, IA 52242

[Support Us](#)

Legal

Copyright © 2019 The University of
Iowa. All Rights Reserved
[Report an issue with this page](#)
[Web Privacy Policy](#) |
[Nondiscrimination Statement](#)

Related Links

[Cataract Surgery for Greenhorns](#)
[EyeTransillumination](#)
[Gonioscopy.org](#)
[Iowa Glaucoma Curriculum](#)
[Iowa Wet Lab](#)
[Patient Information](#)
[Stone Rounds](#)
[The Best Hits Bookshelf](#)

EyeRounds Social Media

Follow



[Receive notification of new cases,
sign up here](#)
[Contact Us](#)
[Submit a Suggestion](#)